

## “The Nitty Gritty of it All”: Meconium Periorchitis

Saryu Gupta<sup>1</sup>, Manoj Mathur<sup>2</sup>

<sup>1</sup> Assistant Professor, Department Of Radiodiagnosis And Imaging, Government Medical College And Rajindra Hospital, Patiala (Punjab) India

<sup>2</sup> Associate Professor, Department Of Radiodiagnosis And Imaging, Government Medical College And Rajindra Hospital, Patiala (Punjab) India

---

**Abstract:** Meconium periorchitis is a bizarre albeit rare extra- abdominal sequel of fetal meconium peritonitis; ensuing the passage of meconium into the scrotum via a patent processus vaginalis. We hereby present the case of a 20 day old male neonate with the sonographic, peroperative and histopathological correlates of Meconium Periorchitis. The scrotal meconium being predestined for calcification and resorption, an expectant management with meticulous surveillance is acceptable. Surgical exploration is however warranted for ambiguous masses and in those with progressive scrotal enlargement. Infact a diligent and mandatory antenatal scrotal evaluation allows early diagnosis of this entity and averts needless orchidectomy in the neonate.

**Keywords:** Meconium, Periorchitis, Scrotum

---

### I. Introduction

Meconium periorchitis, first elucidated in 1953 by Olnick and Hatcher,(1) is an infrequent antenatal and perinatal oddity. Antenatal fetal bowel perforation with subsequent intraperitoneal extravasation of meconium incites a sterile chemical peritonitis. Subsequently meconium extrudes into the para-testicular soft tissues through a patent processus vaginalis and precipitates reactive inflammatory changes with resultant fibrosis and dystrophic calcification.(2)

### II. Study Case

A 20 day-old term neonate was referred to our department from the department of surgery with the provisional diagnosis of bilateral congenital hydroceles.(Figure 1) The baby had been delivered normally after an uneventful pregnancy with nothing contributory in the antenatal or postnatal records. A hard, gritty- feel, painless, non-tender mass not clearly separable from the left testis was palpable. The testes were normally descended. Serum tumour markers and screening for cystic fibrosis were negative.

On imaging the right hemiscrotum was unremarkable except for the presence of a small hydrocele with no internal echoes or septae. (Figure 2a & 2b) The left testis positioned within the scrotal sac and measuring approx. 11mm into 7.7 mm in dimensions displayed a grossly normal echopattern with no obvious focal lesion. (Figure 3a) The left epididymis also displayed normal dimensions and echopattern. (Figure 3a)

However, there was visualised a well-defined, ovoid configuration, heterogenous echopattern mass within the left tunica vaginalis cavity. (Figure 4a) This was distinctly separate from the ipsilateral testis & surrounded by a large septated hydrocele. (Figure 3b) It measured approx. 3.26cm×2.13cm×2.38 cm in dimensions. (Figure 4b) This mass had multiple echogenic foci most of them casting a distal acoustic shadow indicative of calcification. (Figure 4c) No abdominal / peritoneal calcifications were demonstrable on conventional x-rays.

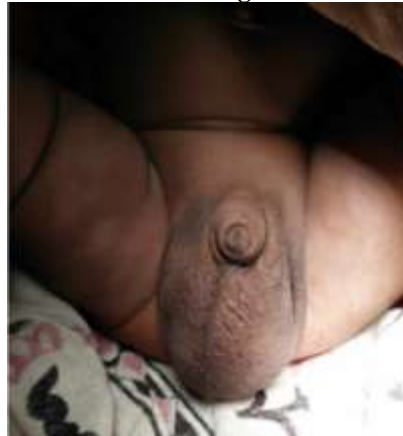Subsequently upon scrotal exploration, a well - circumscribed and firm greenish-coloured para-testicular mass was found adherent to the tunica vaginalis. (Figure 5) The gross pathologic appearance confirmed multiple greenish soft -tissue pieces with gritty yellowish foci measuring 3cm x 2.5cm x 1cm in aggregate. The histopathological examination revealed fibro-connective tissue with abundant myxoid stroma, pigment-laden macrophages and foci of dystrophic calcification --- features consistent with Meconium Periorchitis.

### III. Discussion

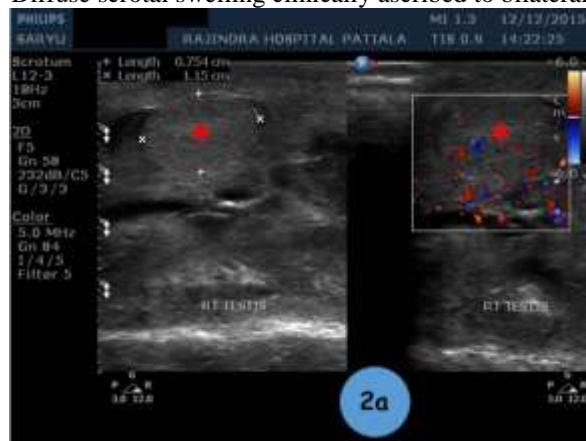
Meconium peritonitis is a rare entity, with an incidence of 1:35 000 live births, usually presenting during or after the 2nd trimester of pregnancy. Various causes of in – utero bowel perforation include intestinal atresia/stenosis, volvulus, intussusception, Meckel’s diverticulum or peritoneal bands.(3) Its extra-abdominal complications include meconium periorchitis, passage into the thoracic cavity through the foramen of Bochdalek as well as systemic embolization. (4)Dystrophic peritoneal calcifications are present in 85% of cases and may form as early as 12 hours post-perforation.(3) The presence of echogenic bowel on antenatal or postnatal ultrasound mandates ruling out trisomy 21, cystic fibrosis and in- utero infections etc.

Meconium periorchitis is a sequel of meconium peritonitis due to extravasation of meconium into the scrotum via a patent processus vaginalis.(5) 25% of infants reveal no scrotal abnormality clinically(4) while bilateral soft reducible hydroceles or scrotal swelling & discolouration erroneously ascribed to birth trauma are the usual presentations.(2) The mean age at diagnosis is 1 month while the insidious cases may present upto 5 years of age. The presence of both abdominal and scrotal calcifications is virtually pathognomonic of MPO. A conservative approach is hence advocated in such cases due to its self-limiting course with spontaneous resolution and resorption of the mass as well as the calcifications.(2) However further workup is recommended for ambiguous cases to exclude entities such as teratoma, rhabdomyosarcoma, metastatic neuroblastoma, testicular torsion, antenatal haematoma, calcifying Sertoli cell tumour, lymphoma, pseudotumours etc. with similar sonographic characteristics.(6)

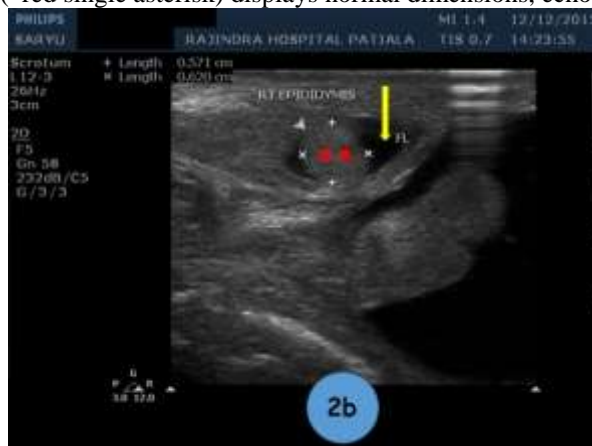#### IV. Figures



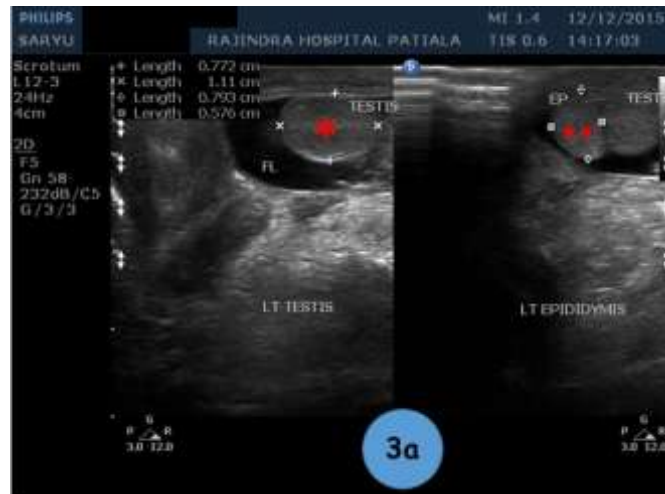**Figure 1:** Diffuse scrotal swelling clinically ascribed to bilateral hydroceles



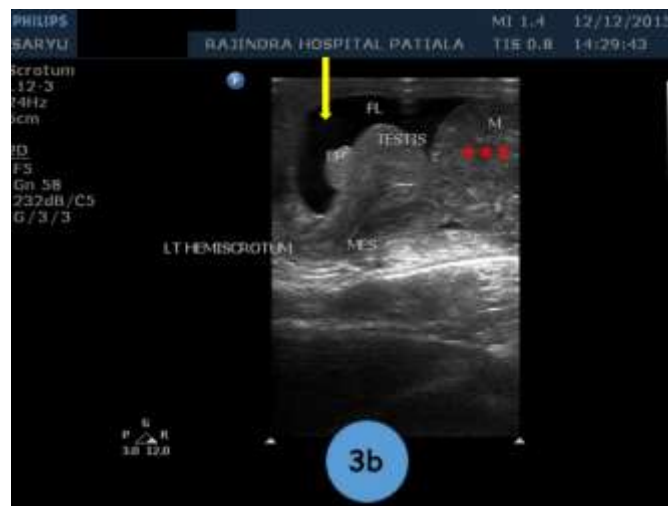**Figure 2a:** Right testis (\*red single asterisk) displays normal dimensions, echopattern and flow on CDFI



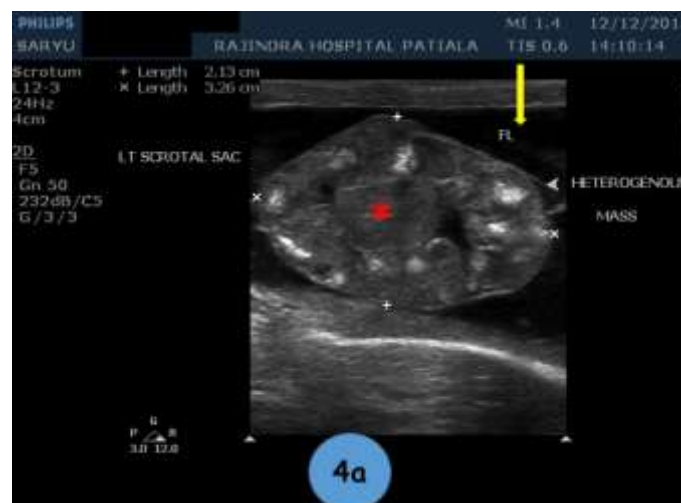**Figure 2b:** Right epididymis (\*\*red double asterisk) displays normal dimensions and echopattern. Note is made of small amount of fluid in the tunica vaginalis cavity (yellow arrow)



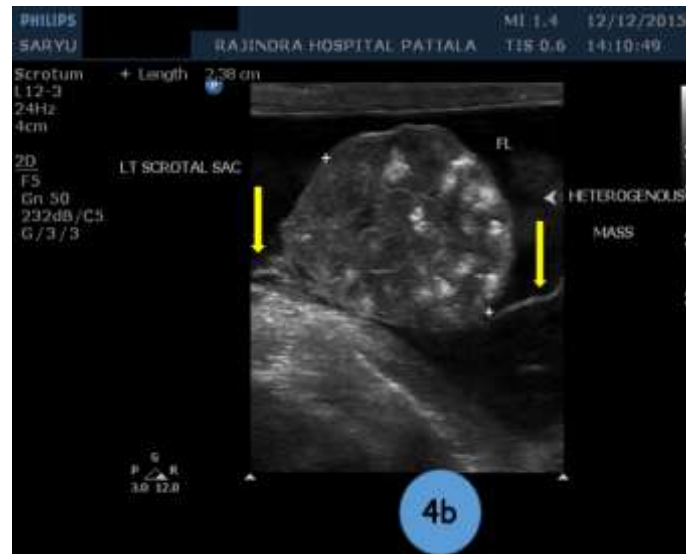**Figure 3a:** Left testis (\*red single asterisk) displays normal dimensions and echopattern. Left epididymis (\*\*red double asterisk) displays normal dimensions and echopattern



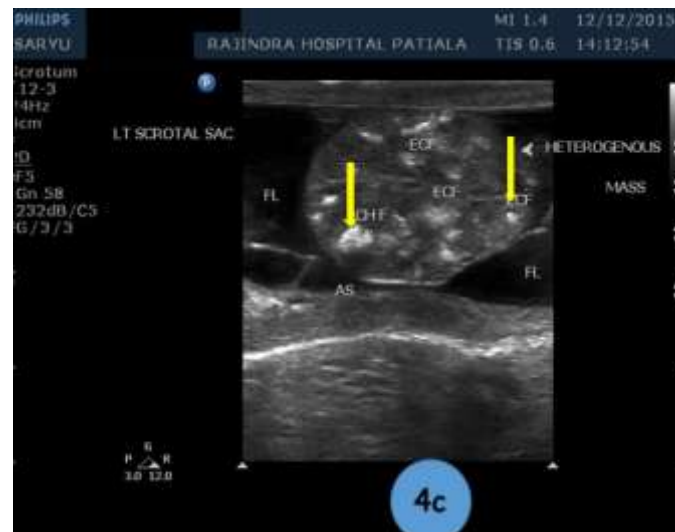**Figure 3b:** Paratesticular mass (\*\*red triple asterisk) is seen closely abutting but separable from the left testis. Fluid is seen in the tunica vaginalis cavity (yellow arrow)



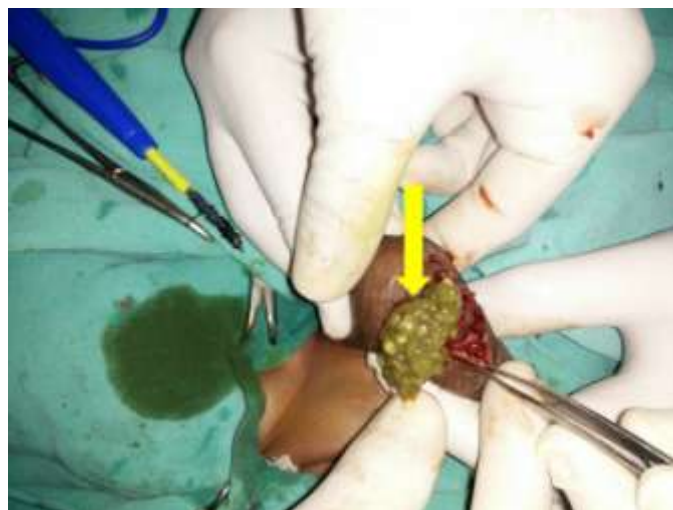
**Figure 4a:** Well-circumscribed left paratesticular mass (\*red single asterisk) with ovoid configuration and heterogenous echopattern. Large amount of fluid is seen in tunica vaginalis cavity (yellow arrow)



**Figure 4b:** Septae are seen within the hydrocele (yellow arrows)



**Figure 4c:** The mass displays multiple echogenic foci which cast a distal acoustic shadow (yellow arrows) indicative of calcification



**Figure 5:** Greenish-coloured paratesticular mass with gritty yellowish foci is discerned upon scrotal exploration (yellow arrows)

## V. Conclusion

MPO is an atypical benign scrotal mass in the neonate.(7) A high index of suspicion among the radiologists, neonatologists and paediatric surgeons will facilitate prompt diagnosis and optimal management of the neonate. High frequency ultrasound with its excellent spatial resolution is an easily accessible and cost-effective tool for detection and subsequent decision-making leading either to a conservative approach or surgical intervention. Atypical cases however do occur which necessitate surgical exploration and histopathological confirmation.

### Declarations

- a. Funding: Nil
- b. Conflict of interest: Nil
- c. Ethical approval: Not Required

### References

- [1]. Cerine Jeanty B, Ana Bircher, MD, Cheryl Turner, BS, RDMS. Prenatal Diagnosis of Meconium Periorchitis and Review of the Literature. *Ultrasound Med.* 2009;28:1729-34.
- [2]. RH Regev OM, S Arnon, S Bauer, T Dolfen, I Litmanovitz. Meconium periorchitis: intrauterine diagnosis and neonatal outcome: case reports and review of the literature. *Journal of Perinatology.* 2009;29:585-7.
- [3]. Vlok S, Plessis Vd. Meconium pseudocyst associated with congenital CMV infection. *S Afr J Rad.* 2015;19(2):3.
- [4]. Thomas E. Herman M, Marilyn J. Siegel M. Meconium Periorchitis. *Journal of Perinatology.* 2004;24:53-5.
- [5]. Ochiai D, Omori S, Ikeda T, Yakubo K, Fukuiya T. A Rare Case of Meconium Periorchitis Diagnosed in Utero. *Case Reports in Obstetrics and Gynecology.* 2015;2015:2.
- [6]. Deeparaj Hegde AU. Meconium Periorchitis. *Indian Pediatrics.* 2015;52:449.
- [7]. Ammar Hameed Alanbuki MAB, MD; Nick Blackford, MD. Meconium periorchitis: A case report and literature review. *Can Urol Assoc J.* 2013;7(7-8):e496-98.